

Chapter 5 X-rays and CT

1. X-ray imaging of small objects

Accidental ingestion of foreign bodies is a common problem in children. One such recent hazard is the ingestion of small, rare-earth magnets from toys. When ingested, the magnets can have potentially lethal consequences if not immediately treated. The magnets may lodge in the esophagus, the stomach, or in any segment of the bowel. In the stomach or bowel, the magnets can bind together to form obstructions, which can lead to severe complications if left untreated. According to the American Academy of Pediatrics 100’s of cases of magnet ingestion are reported annually by emergency rooms across the US. These toys sold could contain hundreds of small magnets and it’s hard to tell if a few have gone missing by say a parent. An image of such a toy is shown below in Figure 1.




Figure 1: An ad from Amazon.com showing a set of 216 5-mm spherical magnets that you can buy as a toy for

Consider the film x-ray image shown below (Figure 2) taken of a 3-year-old boy in the ER showing seven magnets lodged in his lower esophagus and upper stomach. The upper two magnets are in the esophagus while the remaining lower five are in the upper stomach.

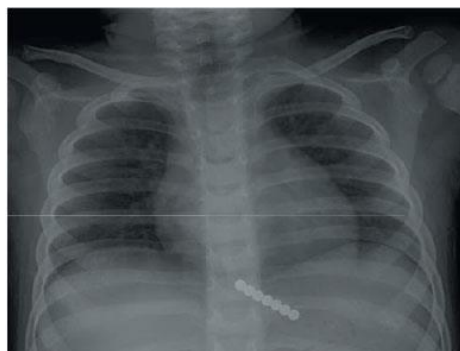

Figure 2: X-ray image of a 3-year-old child with a set of magnets lodged in his gastro-intestinal tract.

[http://www.scielo.org.za/scielo.php?script=sci\\_arttext&pid=S0256-95742014000400017#f1](http://www.scielo.org.za/scielo.php?script=sci_arttext&pid=S0256-95742014000400017#f1)

- a. To form the x-ray image, suppose that the beam of x-rays was directed through the child from front-to-back as in the image shown in Figure 2. Let the cartoon diagram, shown in Figure 3 represent the structures in the body that the x-ray beam passed through. Further, let the intensity of the emerging x-ray beam on the detector be 0.04% of the incident beam intensity, or  $I_{detector} = 0.0004I_0$ . From the information in Table 1 and using Figure 3, how thick was the magnet the child ingested? The magnet is colored blue in Figure 3. Assume that the x-ray beam goes through 0.5cm of fat on the belly, 9cm of liver tissue, 0.4cm of stomach wall muscle, 5.2cm of air in the stomach, another 0.4cm of stomach wall muscle, 4cm of the vertebra of the spine, 0.5cm of fat on the back, and of course the magnet in the stomach. Absorption coefficients and densities of the various structures in the body are given in Table 1.

Structure	$m_m \left( \frac{cm^2}{g} \right)$	$r \left( \frac{g}{cm^3} \right)$
Magnet	10.3	6.9
Fat/Liver	0.1974	0.95
Stomach/Muscle	0.2048	1.05
Bone	0.3148	1.92
Air	0.1875	0.0012

Table 1: X-ray mass attenuation coefficients and densities of various materials.

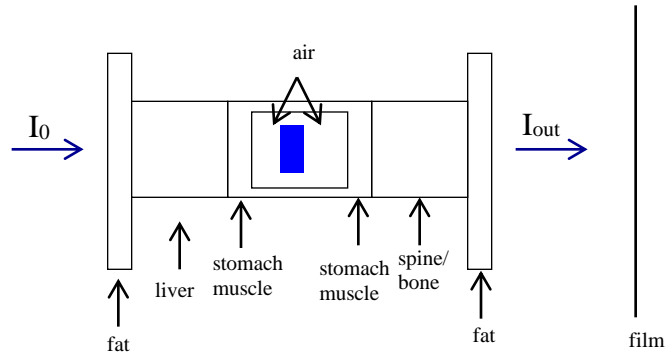


Figure 3: Cartoon version of the path that the x-ray beam takes through the child.

- b. Instead of magnet, suppose that a patient presents in the ER complaining of chronic (happening for a long time) stomach pain. It is believed by the ER physician that the patient may be suffering from a stomach ulcer. Stomach ulcers are painful sores that develop in the stomach lining. The attending ER physician and a new resident physician have different ideas on how to best see the ulcer. The resident physician would like to image the ulcer using an x-ray scan while the ER physician would like to try something else. Suppose that the ulcer can be modeled by blood ( $\mu_{m,blood} = 0.2057 \frac{cm^2}{g}$ ;  $\rho_{blood} = 1.06 \frac{g}{cm^3}$ ) and the resident physician wanted to see a  $0.25cm$  thick ulcer in the lining of the stomach wall, what is the contrast between the ulcer and the stomach wall? Assume that the lining of the stomach can be modeled by muscle and use Table 1.

c. Comment on the result that you get using x-rays to image an ulcer. Do you think the resident physician is right? Can you image the ulcer on an x-ray scan? Explain why or why not.

d. Assuming the resident physician is incorrect and that you cannot image the ulcer on an x-ray image, suggest at least one way the attending ER physician would probably use to see the ulcer.